

Criteria Grid
Hepatitis C Research Studies, Tools, and Surveillance Systems

Best Practice/Intervention:	Fabrizi F. et al. (2012) Antiviral therapy for HCV-associated cryoglobulinemic glomerulonephritis: case report and review of the literature. <i>Kidney & Blood Pressure Research</i> , 35(6):687-693			
Date of Review:	March 11, 2015			
Reviewer(s):	Christine Hu			
Part A				
Category:	Basic Science <input type="checkbox"/> Clinical Science <input type="checkbox"/> Public Health/Epidemiology <input type="checkbox"/> Social Science <input type="checkbox"/> Programmatic Review <input checked="" type="checkbox"/>			
Best Practice/Intervention:	Focus: Hepatitis C <input checked="" type="checkbox"/> Hepatitis C/HIV <input type="checkbox"/> Other: cryoglobulinemic glomerulonephritis Level: Group <input checked="" type="checkbox"/> Individual <input type="checkbox"/> Other: _____ Target Population: <u>patients with HCV-associated glomerulonephritis</u> Setting: Health care setting/Clinic <input checked="" type="checkbox"/> Home <input type="checkbox"/> Other: _____ Country of Origin: <u>Italy</u> Language: English <input checked="" type="checkbox"/> French <input type="checkbox"/> Other: _____			
Part B				
	YES	NO	N/A	COMMENTS
<i>Is the best practice/intervention a meta-analysis or primary research?</i>	<input checked="" type="checkbox"/>	<input type="checkbox"/>	<input type="checkbox"/>	meta-analysis; case report of successful antiviral treatment in a 51 year old women with HCV-associated cryoglobulinemic glomerulonephritis (GN) and systematic review of efficacy and safety of therapy for HCV-associated GN
<i>Has the data/information been used for decision-making (e.g. program funding developments, policies, treatment guidelines, defining research priorities and funding)?</i>	<input type="checkbox"/>	<input checked="" type="checkbox"/>	<input type="checkbox"/>	Article suggested that further studies are required on long-term outcomes of rituximab (RTX) treatment before wide implementation of the treatment strategy.
<i>Do the methodology/results described allow the reviewer(s) to assess the generalizability of the</i>	<input checked="" type="checkbox"/>	<input type="checkbox"/>	<input type="checkbox"/>	

<i>results?</i>				
<i>Are the best practices/methodology/results described applicable in developed countries?</i>	<input checked="" type="checkbox"/>	<input type="checkbox"/>	<input type="checkbox"/>	Prevalence of GN is low and available evidence is limited, with the most survey done on male veterans hospitalized in USA in the 1990s. Studies included in review originate only from Italy and France.
	YES	NO	N/A	COMMENTS
<i>Are the best practices/methodology/results described applicable in developing countries?</i>	<input type="checkbox"/>	<input checked="" type="checkbox"/>	<input type="checkbox"/>	
<i>The research study/tool/data dictionary is easily accessed/available electronically</i>	<input checked="" type="checkbox"/>	<input type="checkbox"/>	<input type="checkbox"/>	Available to download from http://www.karger.com
<i>Is there evidence of cost effective analysis with regard to interventions, diagnosis, treatment, or surveillance methodologies? If so, what does the evidence say? Please go to Comments section</i>	<input type="checkbox"/>	<input checked="" type="checkbox"/>	<input type="checkbox"/>	
<i>Are there increased costs (infrastructure, manpower, skills/training, analysis of data) to using the research study/tool/data dictionary?</i>	<input type="checkbox"/>	<input checked="" type="checkbox"/>	<input type="checkbox"/>	
<i>How is the research study/tool funded? Please got to Comments section</i>	<input checked="" type="checkbox"/>	<input type="checkbox"/>	<input type="checkbox"/>	The study was supported in part by the grant 'Project Glomerulonephritis' in memory of Pippo Neglia.
<i>Is the best practice/intervention dependent on external funds?</i>	<input type="checkbox"/>	<input checked="" type="checkbox"/>	<input type="checkbox"/>	
<i>Other relevant criteria:</i> _____	<input type="checkbox"/>	<input type="checkbox"/>	<input type="checkbox"/>	<ul style="list-style-type: none"> - Limited studies on the antiviral therapy of HCV-related GN - Long-term impact of therapy is unclear
WITHIN THE SURVEILLANCE SYSTEM FOR REVIEW				
<i>Are these data regularly collected?</i>	<input type="checkbox"/>	<input checked="" type="checkbox"/>	<input type="checkbox"/>	Search of medical literature up to August 31, 2012
<i>Are these data regularly collected at and/or below a national level?</i>	<input type="checkbox"/>	<input checked="" type="checkbox"/>	<input type="checkbox"/>	
<i>Are these data collected manually or electronically?</i>	<input type="checkbox"/>	<input type="checkbox"/>	<input type="checkbox"/>	Electronically: PubMed search
RESEARCH REPORTS				

<i>Has this research been published in a juried journal?</i>	<input checked="" type="checkbox"/>	<input type="checkbox"/>	<input type="checkbox"/>	<i>Kidney & Blood Pressure Research</i>
<i>Does the evidence utilize the existing data/surveillance information or has it generated new data and/or information?</i>	<input type="checkbox"/>	<input type="checkbox"/>	<input type="checkbox"/>	utilize existing data/surveillance information: six studies included in review

Antiviral Therapy for HCV-Associated Cryoglobulinemic Glomerulonephritis: Case Report and Review of the Literature

Fabrizio Fabrizi^a Giovanni Battista Fogazzi^a Donata Cresseri^a Patrizia Passerini^a
Paul Martin^c Maria Francesca Donato^b Maria Grazia Rumi^b Piergiorgio Messa^a

^aDivision of Nephrology, Maggiore Hospital, IRCCS Foundation, and ^bDivision of Gastroenterology, Maggiore Hospital and University School of Medicine, Milan, Italy; ^cDivision of Hepatology, School of Medicine, University of Miami, Miami, Fla., USA

Key Words

Hepatitis C · Glomerulonephritis · Cryoglobulinemia · Interferon · Rituximab

Abstract

We describe the case of a 51-year-old woman with HCV-associated cryoglobulinemic glomerulonephritis (GN). She presented mild deterioration of kidney function, non-nephrotic proteinuria, and active urinary sediment. Kidney biopsy showed features of membranoproliferative changes with some sclerosis. Sustained viral response (SVR) was obtained by 6 months of antiviral therapy (peg-IFN- α 2a plus ribavirin). SVR was linked with improvement of kidney function and remission of proteinuria. Clinical and virological remission persists over a 25-month follow-up. This case report emphasizes efficacy and safety of antiviral treatment of HCV-associated glomerulonephritis – preliminary but encouraging results exist. We identified by systematic review of the literature 9 studies (156 unique patients); the pooled estimate of frequency of sustained virological response after IFN-based therapy was 0.49 (95% confidence interval, CI: 0.21, 0.77; $p < 0.0005$; random effects model). Heterogeneity was found ($I^2 = 98.9\%$, $p < 0.0001$). Two possible regimens should be considered for the treatment of HCV-associated

cryoglobulinemic GN according to the clinical presentation. Immunosuppressive therapy is recommended for HCV-related kidney disease having aggressive course, and recent evidence supports rituximab (RTX) use with a reduced exposure to corticosteroids. We identified six studies (66 unique patients) on RTX therapy for HCV-associated kidney disease; at the end of RTX therapy, the pooled estimate of the mean decrease in proteinuria was 1.4 g/24 h (95% CI: 0.75, 2.05, $p < 0.001$); The p test for heterogeneity gave a value of 0.94 ($I^2 = 0$). Several questions related to RTX use remain. HCV-induced GN is uncommon among CKD patients of developed countries, and this clearly hampers prospective controlled clinical trials aimed to evaluate efficacy and safety of antiviral or immunosuppressive therapy in this population.

Copyright © 2013 S. Karger AG, Basel

Introduction

Patients with long-standing HCV infection can develop chronic hepatitis, liver cirrhosis, and hepatocellular carcinoma. Several extrahepatic complications have also been associated with HCV including hematologic and dermatologic diseases as well as autoimmune and kidney diseases [1]. A strong relationship between HCV infec-

tion and cryoglobulinemia has been found since early 1990s [2, 3]. More recent evidence has been accumulated showing a link between HCV infection and immune complex glomerular diseases, including membranoproliferative glomerulonephritis (MPGN) and membranous nephropathy [4–7]. Less frequently described lesions are MPGN without cryoglobulinemia, focal segmental glomerulosclerosis, IgA nephropathy or fibrillary and immunotactoid glomerulopathies [4–7]. Hepatitis C virus-associated tubulointerstitial injury has also been reported [8].

The discovery of HCV and a better understanding of pathophysiological mechanisms provided the opportunity to control HCV-associated MPGN using various approaches: (1) antiviral therapy based on the belief that the underlying infection is driving immune complex formation and resultant vasculitis; (2) non-specific immunosuppressive therapy targeting inflammatory cells present in vasculitic lesions, and (3) B cell depletion therapy targeting B cells which produce cryoglobulins. It is clear that prospective randomized, controlled clinical trials (RCTs) are mandatory to make evidence-based recommendations to treat HCV-associated glomerulonephritis (GN) [9]. Until this information is available, two possible regimens have been recommended for the treatment of cryoglobulinemic or non-cryoglobulinemic HCV-associated GN, depending on the severity of proteinuria and kidney failure (table 1). In patients with moderate proteinuria and slow loss of kidney function, antiviral therapy targeted at achieving clearance of HCV RNA with sustained viral response (SVR) has been successfully used. The use of steroid pulses with cytotoxic agents and plasma exchange has been suggested for patients with nephrotic proteinuria, and/or rapidly progressive loss of kidney function and an acute flare of cryoglobulinemia; after control of the vasculitic syndrome has been achieved, antiviral therapy should be started [9].

We report herein a case of HCV-related MPGN that was successfully treated with antiviral therapy. A systematic review of the literature on the efficacy and safety of therapy for HCV-associated GN was also performed.

Case Report

A 51-year-old Caucasian female was diagnosed with chronic hepatitis C (genotype 2) in May 1998. She showed palpable purpura that was first treated with methotrexate, chloroquine, and then low-dose oral corticosteroids. In June 1998, electromyography revealed axonal neuropathy with sensitive abnormalities of the legs. In January 2009, she was admitted to the Division of Di-

Table 1. Treatment of HCV-related glomerular disease according to the clinical presentation

<i>Patients with mild proteinuria and slow progressive kidney failure</i>	
–	Anti-HCV therapy for 12 months
–	Pegylated IFN α 2a: 180 μ g/week SQ (135 μ g/week in patients with reduced glomerular filtration rate)
–	Pegylated IFN α 2b: 1.5 μ g/kg/week SQ (1.0 μ g/week in patients with low GFR)
–	Ribavirin 800–1,200 mg day orally (for patients with GFR <50 ml/min: low ribavirin dose, 200–600 mg/day, and erythropoietin supplementation)
–	Symptomatic therapy: ACE inhibitors and/or angiotensin receptor blockers to reduce proteinuria, diuretics
<i>Patients with nephrotic proteinuria and/or progressive kidney failure</i>	
–	Methylprednisolone pulses: 0.5–1.0 g/day for three consecutive days, then oral corticosteroids
–	Cyclophosphamide: 1.5–2.0 mg/kg/day (2–4 months; oral route)
–	RTX: 375 mg/m ² /week for 4 weeks (intravenous route)
–	Plasma exchange: 3 l of plasma thrice weekly for 2–3 weeks
–	Anti-HCV therapy for 12 months (as shown above)
–	Symptomatic therapy (as shown above)

gestive Diseases, Maggiore Hospital, for multifactorial anemia (at that time, serum creatinine 1.36 mg/dl). Several erosions at the duodenum with active bleeding were detected by endoscopy. Beginning in September 2009, the patient had a progressive decline of the kidney function (serum creatinine rose from 1.36 to a maximum of 1.67 mg/dl) with non-nephrotic proteinuria (2 g/24 h). Arterial hypertension occurred, and therapy with angiotensin-converting enzyme inhibitors and angiotensin receptor blockers was instituted with a small benefit on proteinuria. The patient was admitted (October 2009) to the Nephrology Division, Maggiore Hospital, and renal biopsy was performed. On physical examination, palpable purpura extended to the trunk with bilateral edema of the lower extremities. Serum creatinine was 1.3 mg/dl, anti-HCV positive, HCV RNA positive (13,762 copies/ml), cryocrit was 1%, rheumatoid factor 276 IU/l (0–14 IU/l), and C4 concentration 10 mg/dl (17–33 mg/dl). She had a monoclonal IgMk cryoglobulin with a polyclonal IgG component. Normal serum immunoglobulins (IgG, IgA, IgM), complement C₃ and electrophoresis were found. Several serologic markers were in the normal range including anti-nuclear antibody, anti-double-stranded DNA (anti-DNA), and anti-neutrophil cytoplasmic antibodies. Other findings included GOT 16 IU/l, GPT 9 IU/l, γ -glutamyltranspeptidase 8 IU/l, and total bilirubin 0.15 mg/dl. Proteinuria was 1.13 g/24 h, and urine sediment, analyzed by phase-contrast microscopy, showed severe microscopic hematuria (90–100 erythrocytes/microscopic field, 56% having dysmorphic nature, 12% acanthocytes), and numerous granular, and red cell casts. Kidney histology showed 21 glomeruli, 16 of which were diffusely and uniformly abnormal with features characteristic of membranoproliferative nephritis (double contour appearance of the capillary wall, centrolobular sclerosis, mesangial cell proliferation, endoluminal mononuclear cells, and mesangial matrix expansion).

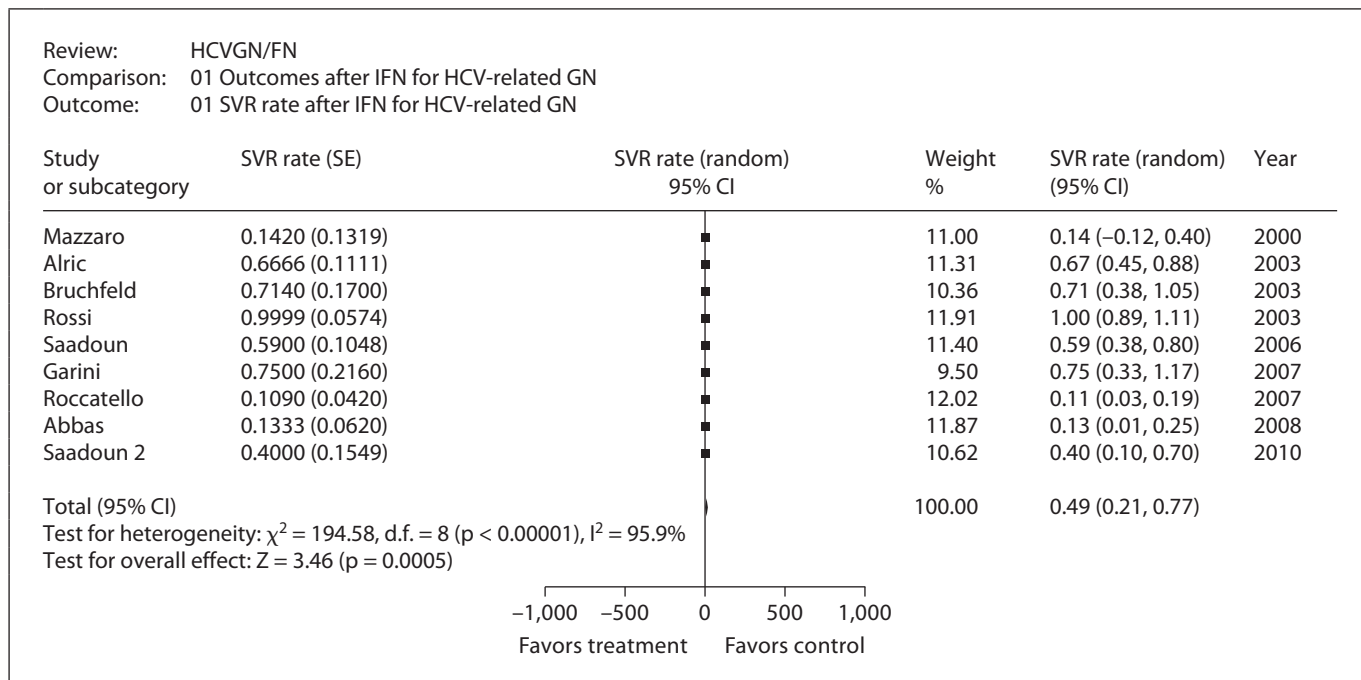


Fig. 1. HCV-related GN: viral response after IFN.

Global sclerosis was observed in five glomeruli. Interstitial fibrosis and moderate atherosclerosis were also present. Immunofluorescence exhibited isolated IgM deposition in sclerotic areas. Antiviral therapy was started (subcutaneous administration of peg-IFN- α 2a 180 μ g weekly and oral ribavirin 400 mg twice a day), and prednisone therapy (5 mg on alternate days) was continued. Subcutaneous darbepoetin (40 μ g weekly) was also given.

Complete resolution of the cutaneous manifestations and edema was noted after a few weeks of antiviral therapy. The patient required transfusion with 3 units of packed red blood cells (January 2010) due to severe anemia (Hb 6.8 g/dl); thus, therapy was modified as follows: peg-IFN- α 135 μ g s.c. weekly, ribavirin 200 mg twice a day, no prednisone, and darbepoetin dose progressively was increased to 100 μ g weekly. HCV RNA clearance occurred in January 2010. Antiviral therapy was discontinued in April 2010; at that time, the patient had normal protein excretion (0.09 g/24 h) with very mild microscopic hematuria. A slow improvement of kidney function was found with serum creatinine 1.16 mg/dl. HCV RNA and serum cryoglobulin tests were repeatedly negative. Twenty-five months after completing antiviral therapy (May 2012), continued follow-up showed stable clinical conditions – proteinuria of 0.15 g/24 h, serum creatinine 1.13 mg/dl (glomerular filtration rate according to MDRD equation of 63 ml/min) and mild microscopic hematuria (2–4 erythrocytes/microscopic field, 54% of them dysmorphic; no acanthocytes, no casts). Normal serum complement (C_3/C_4) was noted. Her medications currently include nifedipine, ranitidine, and doxazosin.

Review of the Literature

A systematic review of the medical literature was done by PubMed search up to August 31, 2012; the key words ‘cryoglobulinemia’, ‘glomerulonephritis’, ‘HCV infection’, ‘interferon’, ‘rituximab’ were used to identify clinical studies on antiviral (or rituximab, RTX) treatment of HCV-associated kidney disease. Review papers and case reports were excluded. Some manuscripts were excluded as they gave information on patients already reported in prior publications [10, 11], others gave incomplete results [12–18].

We identified 9 clinical studies on antiviral therapy for HCV-associated GN (n = 156 unique patients; fig. 1) [19–27]; the rate of SVR ranged between 14 and 100%. As listed in figure 1, the summary estimate of frequency of SVR was 0.49 (95% confidence interval, CI: 0.21, 0.77; random-effects model). Significant heterogeneity was noted.

A total of six studies on RTX for HCV-associated glomerular disease was considered in this review [28–33]; only these satisfied our inclusion criteria, i.e. detailed information on HCV-associated kidney disease at baseline and over follow-up. Various reports on RTX therapy for symptomatic HCV-associated mixed cryoglobulinemia

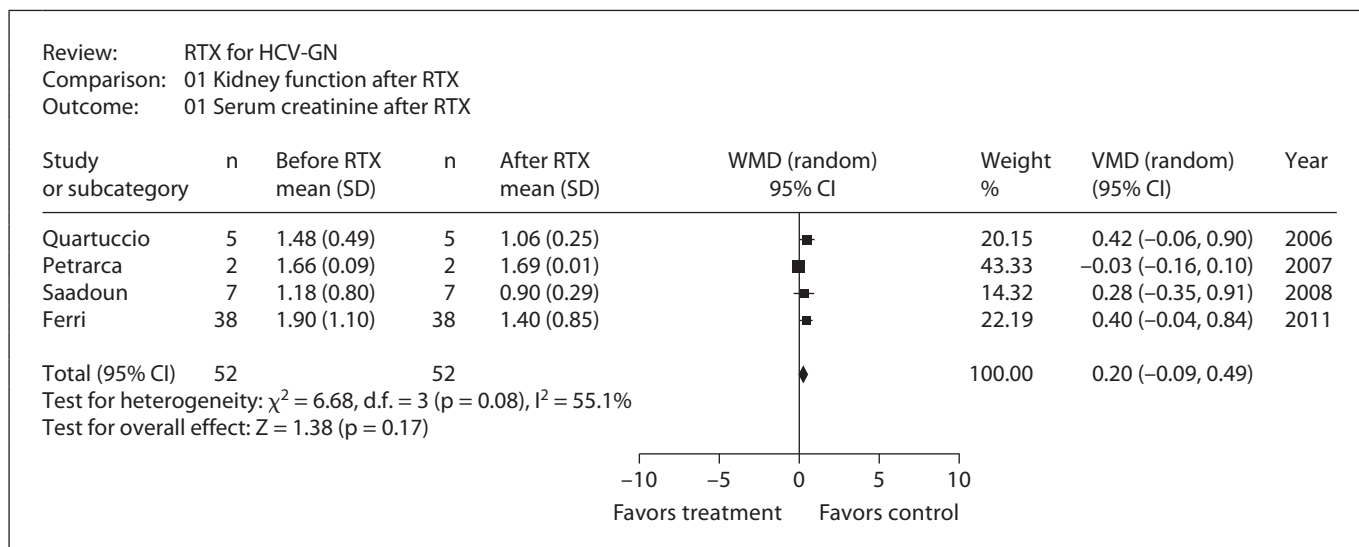


Fig. 2. HCV-related GN: serum creatinine after RTX.

(HCV-MC) with kidney involvement have been published; some of them mentioning the ‘partial’ or ‘complete’ remission of kidney disease after RTX, but no clear information on daily proteinuria or serum creatinine was given [34–35]. The number of patients with kidney disease was small (66 unique patients; table 2); renal involvement ranged from proteinuria, nephrotic or nephritic syndrome, to chronic kidney disease. All patients had symptomatic HCV-MC, the majority being non-cirrhotic with HCV genotype 1. As shown in table 3, RTX appears effective for HCV-related kidney disease; the pooled mean difference of decrease in serum creatinine after RTX was 0.20 mg/dl (95% CI: -0.09, 0.49; $p = 0.55$), no heterogeneity was noted ($p = 0.08$; $I^2 = 55.1\%$; fig. 2). Information on daily proteinuria was given in three reports only; the pooled mean difference of proteinuria decrease after RTX was 1.40 g/24 h (95% CI: 0.75, 2.05; $p < 0.0001$); p test for heterogeneity was not significant.

Discussion

HCV has been associated with glomerular lesions in native and transplanted kidneys. The exact prevalence of these renal manifestations is probably low, and the available evidence on this issue is limited; to date, the most important survey has been done on male veterans hospitalized in the USA in the 1990s [36]; membranoproliferative GN was more frequent among HCV positive- than

HCV-negative individuals (0.36 vs. 0.05%, $p < 0.0001$). No difference occurred on membranous nephropathy (0.33 vs. 0.19%, $p = 0.86$).

Our case emphasizes the efficacy of antiviral therapy for HCV-associated GN; the mild kidney disease and the absence of aggressive involvement of other organs suggested an antiviral approach. We observed a close relationship between persistent clearance of HCV viremia and remission of urinary abnormalities. Tolerance to antiviral therapy was not excellent as the patient needed blood transfusions; however, this side effect disappeared after dose reduction of antiviral drugs. She received a 6-month course of antiviral therapy even if the KDIGO guidelines recommend antiviral therapy for at least 12 months irrespective of HCV genotype [9].

Our systematic review demonstrated the limited number of studies addressing the antiviral therapy of HCV-related GN, only small observational studies exist [37]. In addition, the impact of antiviral therapy on long-term outcomes of kidney disease remains unclear. As reported in figure 1, initial studies (based on IFN alone) not surprisingly gave high relapse rates, but with the gold standard of HCV treatment (pegylated IFN plus ribavirin), the viral response was better. Of note, in all patients with proteinuria reduction, HCV RNA clearance was documented at the end of IFN therapy.

With multiorgan involvement, the antiviral therapy may be limited due to treatment failure, adverse effects, contraindications, or severe renal disease. On the other

Table 2. Rituximab therapy of HCV-associated cryoglobulinemic GN: baseline characteristics and RTX schedule

	First author					
	Quartuccio	Petrarca	Roccatello	Saadoun	Ferri	De Vita
Year	2006	2007	2008	2008	2011	2012
Country	Italy	Italy	Italy	France	Italy	Italy
Patients	5	2	12	16	87	28
Age, years	57.2 (45–65)	61.5	61.9 (37–76)	58 ± 10.5	61.3 ± 11.4	62.8 ± 11.4
Male	1 (20%)	1 (50%)	NA	3 (19%)	19 (22%)	4 (14%)
HCV genotype 1	3 (60%)	NA	6 (54%)	10 (62%)	NA	NA
Prior antiviral therapy	2 (40%)	1 (50%)	0	7 (100%)	NA	14 (50%)
Rheumatoid factor, IU/ml	1.783 (146–3,910)	14,207	512 (272–750)	173.3 ± 55.7	NA	501.4 ± 891
C4, mg/dl	6.2 (2–12)	6.5 (1–12)	5.2 (4–8)	6.2 ± 9	NA	6.27 ± 8.7
IgM, mg/dl	387.2	NA	480 (250–650)	180 ± 700	NA	NA
Kidney disease	5 (100%)	2 (100%)	7 (58%)	7 (43.8%)	38 (43.6%)	7 (25%)
Purpura	80%	100%	NA	81%	59%	NA
Skin ulcers	0	0	3 (25%)	2 (12.5%)	24 (27%)	5 (17.8%)
Hepatitis or cirrhosis	5 (100%)	2 (100%)	NA	4 (25%)	52 (60%)	NA
Peripheral neuropathy	2 (40%)	2 (100%)	12 (100%)	13 (81%)	69 (79%)	16 (57%)
RTX schedule	375 mg/m ² per week (4 doses)	375 mg/m ² per week (4 doses)	375 mg/m ² per week (4 + 2 doses)	375 mg/m ² per week (4 doses) + pegIFNα2b and ribavirin	375 mg/m ² per week (4 doses) or 1 g × 2 (0, 14 day)	1 g × 2 (0, 14 day)

NA = Not available.

Table 3. RTX therapy of HCV-associated cryoglobulinemic GN: follow-up results on proteinuria (g/24 h) and serum creatinine (mg/dl)

First author	Daily proteinuria baseline/follow-up	Serum creatinine baseline/follow-up
Ferri	2.2 ± 2.1/0.9 ± 1.75	1.8 ± 1.1/1.4 ± 0.85
Roccatello	1.6/0.3	NA
Quartuccio	1.74 ± 1.3/0.2 ± 0.2	1.48 ± 0.49/1.06 ± 0.25
De Vita	2 (0.6–7.9)/0.9 (0.5–4.5)	1.6 (0.7–2.8)/1.6 (0.8–0)
Petrarca	NA	1.66 ± 0.09/1.69 ± 0.01
Saadoun	1.6 ± 2.5/0.1 ± 0.2	1.18 ± 0.8/0.9 ± 0.29

NA = Not available.

hand, conventional immunosuppressive therapy may be poorly tolerated or ineffective. Therefore, new treatment options such as RTX, a human-mouse chimeric monoclonal antibody, have been proposed. RTX binds to the B cell surface antigen CD20 and depletes the expanded B cell clone or clones producing rheumatoid factor and cryoglobulins. Several groups have first reported on the efficacy of RTX in patients with symptomatic HCV-MC vasculitis resistant or intolerant to IFN-α monotherapy. A complete clinical response was reported in 60–70% of cases, with cryoglobulin clearance in one third of patients

[34, 35]. Recently, two RCTs showed that RTX was superior to conventional immunosuppressive agents (i.e. corticosteroids, plasma exchange, and azathioprine or cyclophosphamide) for treating symptomatic HCV-MC [33, 38]. No change in HCV viral load was noted following RTX therapy, according to one RCT [38]; in another RCT, the frequency of adverse side effects was higher in the RTX than the control group, even if the difference did not reach statistical significance (21.5 vs. 10%) [33]. Thus, a word of caution is important as the use of RTX has been associated with the activation of various infections, particularly after solid organ transplantation [39, 40].

The absence of efficacy on HCV clearance is a matter of concern, and the high relapse rates observed in some reports support the need for antiviral therapy to block the infection trigger and obviate long-term liver complications. A recent prospective controlled trial showed the superiority of a combination of RTX plus Peg-IFN-α2b-ribavirin compared to Peg-IFN-α2b-ribavirin alone in symptomatic HCV-MC. A complete clinical response was noted in 80.9% (17/21) of patients with kidney involvement in the RTX plus Peg-IFN-α2b-ribavirin group, the CR being 40% (4/10) among patients with kidney disease on Peg-IFN-α2b-ribavirin alone ($p < 0.04$) [27]. Thus, the association of RTX with combined antiviral therapy may be an appropriate choice for symptomatic HCV-MC, but its safety and efficacy needs to be better addressed.

Two direct-acting antiviral agents, boceprevir and telaprevir, have been recently licensed; they lower the activity of the HCV non-structural protein 3-4A serine protease and increase the viral response in genotype 1 HCV infection when used in combination with Peg-IFN and ribavirin [41–42]. Novel guidelines now recommend the triple antiviral therapy for treatment of genotype 1 HCV infection [43]. No studies evaluating efficacy and safety of triple therapy for patients with symptomatic HCV-MC exist, and evidence on direct-acting anti-HCV agents is currently limited to patients with intact kidney function.

Another alternative treatment for HCV-associated MC vasculitis is low-dose interleukin-2 (IL-2), a cytokine that promotes survival and function of regulatory T cells (Tregs). Patients with vasculitis induced by HCV have reduced levels of Tregs. Resolution of HCV infection correlates with cure of vasculitis and the recovery of Treg levels. Preliminary data suggest that IL-2 supports an attenuation of inflammatory signs in patients with HCV-

induced vasculitis that was refractory to antiviral therapy, RTX or both [44]. No serious adverse events were noted. Additional studies are essential before wider implementation of this treatment strategy.

In conclusion, our case report emphasizes the efficacy and safety of combined anti-HCV therapy for HCV-positive GN. Viral response was associated with remission of urinary abnormalities and improvement of kidney function. A major concern is the lack of long-term studies on patient/kidney outcomes after treatment of HCV-associated nephropathy. Prospective studies are needed to detail the role of RTX in cryoglobulinemic HCV-positive GN; also, the most effective therapy for relapses of cryoglobulinemia or HCV replication after a successful initial course of treatment remains unclear.

Acknowledgements

This work was supported in part by the grant 'Project Glomerulonephritis' in memory of Pippo Neglia.

References

- Lauer G, Walker B: Hepatitis C virus infection. *N Engl J Med* 2001;345:41–52.
- Pascual M, Perrin L, Giostra E, Schifer J: Hepatitis C virus in patients with cryoglobulinemia type II. *J Infect Dis* 1990;162:567–569.
- Ferri C, Greco F, Longombardo G, Palla P, Moretti A, Marzo E, Foselle P, Pasero G, Bombardieri S: Antibodies to hepatitis C virus in patients with mixed cryoglobulinemia. *Arthritis Rheum* 1991;34:1606–1610.
- Agnello V, Chung R, Kaplan L: A role of hepatitis C infection in type II cryoglobulinemia. *N Engl J Med* 1992;327:1490–1495.
- Fabrizi F, Colucci P, Ponticelli C, Locatelli F: Kidney and liver involvement in cryoglobulinemia. *Semin Nephrol* 2002;22:309–318.
- Johnson R, Willson R, Yamabe H, Couser W, Alpers C, Wener M, Davis C, Gretch D: Renal manifestations of hepatitis C virus infection. *Kidney Int* 1994;46:1255–1263.
- D'Amico G: Renal involvement in hepatitis C infection: cryoglobulinemic glomerulonephritis. *Kidney Int* 1998;54:650–671.
- Kasuno K, Ono T, Matsumori A, Nogaki F, Kusano H, Watanabe H, Yodoi J, Muso E: Hepatitis C virus associated tubulo-interstitial injury. *Am J Kidney Dis* 2003;41:767–775.
- Kidney Disease: Improving Global Outcomes. KDIGO clinical practice guidelines for the prevention, diagnosis, evaluation, and treatment of hepatitis C in chronic kidney disease. *Kidney Int* 2008;73(suppl 109):S1–S99.
- Roccatello D, Baldovino S, Rossi D, Mansouri M, Naretto C, Gennaro M, Cavallo R, Alper M, Costanzo P, Giachino O, Mazzucco G, Sena L: Long-term effects of anti-CD20 monoclonal antibody treatment of cryoglobulinaemic glomerulonephritis. *Nephrol Dial Transplant* 2004;19:3054–3061.
- Garini G, Allegri L, Carnevali L, et al: Interferon alfa in combination with ribavirin as initial treatment for hepatitis C virus-associated cryoglobulinemic membranoproliferative glomerulonephritis. *Am J Kidney Dis* 2001;38:E35–E39.
- Johnson R, Gretch D, Couser W, Alpers C, Willson J, Chung M, Hart J, Willson R: Hepatitis C virus-associated glomerulonephritis. Effect of alpha-interferon therapy. *Kidney Int* 1994;46:1700–1704.
- Stehman-Breen C, Alpers C, Couser W, Willson R, Johnson R: Hepatitis C virus associated membranous glomerulonephritis. *Clin Nephrol* 1995;44:141–147.
- Fabrizi F, Pozzi C, Farina M, Dattolo P, Lunghi G, Badalamenti S, Pagano A, Locatelli F: Hepatitis C virus infection and acute or chronic glomerulonephritis: an epidemiological and clinical appraisal. *Nephrol Dial Transplant* 1998;13:1991–1997.
- Komatsuda A, Imai H, Wakui H, Hamai K, Ohtani H, Kodama T, Oyama Y, Nakamoto Y: Clinicopathological analysis and therapy in hepatitis C virus-associated nephropathy. *Intern Med* 1996;35:529–533.
- Al-Wakeel J, Mitwalli A, Tarif N, Al-Mohaya S, Malik G, Khalil M: Role of interferon-alpha in the treatment of primary glomerulonephritis. *Am J Kidney Dis* 1999;33:1142–1146.
- Beddhu S, Bastacky S, Johnson J: The clinical and morphologic spectrum of renal cryoglobulinemia. *Medicine (Baltimore)* 2002; 81:398–409.
- Colucci G, Manno C, Grandaliano G, Schena FP: Cryoglobulinemic membranoproliferative glomerulonephritis: beyond conventional therapy. *Clin Nephrol* 2011;75:374–379.
- Mazzaro C, Panarello G, Carniello S, Faelli A, Mazzi G, Crovatto M, Baracetti S, Nascimbeni F, Zorat F, Pozzato G, Faccini L, Campanacci L: Interferon versus steroids in patients with hepatitis C virus-associated glomerulonephritis. *Digest Liver Dis* 2000; 32:708–715.
- Bruchfeld A, Lindahl K, Stahle L, Soderberg M, Schvarcz R: Interferon and ribavirin treatment in patients with hepatitis C-associated renal disease and renal insufficiency. *Nephrol Dial Transplant* 2003;18:1573–1580.
- Rossi P, Bertani T, Baio P, Caldara R, Luliri P, Tengattini F, Bellavita P, Mazzucco G, Misiani R: Hepatitis C virus-related cryoglobulinemic glomerulonephritis: long-term remission after antiviral therapy. *Kidney Int* 2003;63:2236–2241.

- 22 Alric L, Plaisier E, Thébault S, Péron JM, Rostaing L, Pourrat J, Ronco P, Piette JC, Cacoub P: Influence of antiviral therapy in hepatitis C virus-associated cryoglobulinemic MPGN. *Am J Kidney Dis* 2004;43:617–623.
- 23 Saadoun D, Resche-Rigon M, Thibault V, Piette J, Cacoub P: Antiviral therapy for hepatitis C-associated mixed cryoglobulinemia vasculitis. *Arthritis Rheum* 2006;54:3696–3706.
- 24 Garini G, Allegri L, Iannuzzella F, Vaglio A, Buzio C: HCV-related cryoglobulinemic glomerulonephritis: implications of antiviral and immunosuppressive therapies. *Acta Biomed* 2007;78:51–59.
- 25 Roccatello D, Fornasieri A, Giachino O, Rossi D, Beltrame A, Banfi G, Confalonieri R, Tarantino A, Pasquali S, Amoroso A, Savoldi S, Colombo V, Manno C, Ponzetto A, Moriconi L, Pani A, Rustichelli R, Barbiano di Belgiojoso G, Comotti C, Quarenghi M: Multicenter study on hepatitis C virus-related cryoglobulinemic glomerulonephritis. *Am J Kidney Dis* 2007;49:69–82.
- 26 Abbas G, Hussain S, Shafi T: Effect of antiviral therapy on hepatitis C virus related glomerulopathy. *Saudi J Kidney Dis Transplant* 2008;19:775–780.
- 27 Saadoun D, Resche Rigon M, Sene D, Terrier B, Karras A, Perard L, Schoindre Y, Coppéré B, Blanc F, Musset L, Piette JC, Rosenzweig M, Cacoub P: Rituximab plus Peg-interferon-alpha/ribavirin compared with Peg-interferon-alpha/ribavirin in hepatitis C-related mixed cryoglobulinemia. *Blood* 2010;116:326–334.
- 28 Quartuccio L, Soardo G, Romano G, Zaja F, Scott C, De Marchi G, Fabris M, Ferraccioli G, De Vita S: Rituximab treatment for glomerulonephritis in HCV-associated mixed cryoglobulinemia: efficacy and safety in the absence of steroids. *Rheumatology* 2006;45:842–846.
- 29 Petrarca A, Rigacci L, Monti M, Giannini C, Bernardi F, Caini P, Colagrande S, Bosi A, Laffi G, Zignego AL: Improvement in liver cirrhosis after treatment of HCV-related mixed cryoglobulinemia with rituximab. *Dig Liver Dis* 2007;39(suppl 1):S129–S133.
- 30 Roccatello D, Baldovino S, Rossi D, Giachino O, Mansouri M, Naretto C, Di Simone D, Francica S, Cavallo R, Alpa M, Napoli F, Sena L: Rituximab as a therapeutic tool in severe mixed cryoglobulinemia. *Clin Rev Allergy Immunol* 2008;34:111–117.
- 31 Saadoun D, Mesche-Rigon M, Sene D, Perard L, Karras A, Cacoub P: Rituximab combined with peg-interferon-ribavirin refractory hepatitis C virus-associated cryoglobulinemia vasculitis. *Ann Rheum Dis* 2008;67:1431–1436.
- 32 Ferri C, Cacoub P, Mazzaro C, Roccatello D, Scaini P, Sebastiani M, Tavoni A, Zignego AL, De Vita S: Treatment with rituximab in patients with mixed cryoglobulinemia syndrome: results of multicenter cohort study and review of the literature. *Autoimmun Rev* 2011;11:48–55.
- 33 De Vita S, Quartuccio L, Isola M, Mazzaro C, Scaini P, Lenzi M, Campanini M, Naclerio C, Tavoni A, Pietrogrande M, Ferri C, Mascia M, Masolini P, Zabotti A, Maset M, Roccatello D, Zignego A, Pioltelli P, Gabrieli A, Filippini D, Perrella O, Migliaresi S, Galli M, Bombardieri S, Monti G: A randomized controlled trial of rituximab for the treatment of severe cryoglobulinemic vasculitis. *Arthritis Rheum* 2012;64:843–853.
- 34 Ahmed M, Wong C: Should rituximab be the rescue therapy for refractory mixed cryoglobulinemia associated with hepatitis C? *J Nephrol* 2007;20:350–356.
- 35 Cacoub P, Delluc A, Saadoun D, Landau DA, Sene D: Anti-CD20 monoclonal antibody (rituximab) treatment for cryoglobulinemic vasculitis: where do we stand? *Ann Rheum Dis* 2008;67:283–287.
- 36 El-Serag H, Hampel H, Yeh C, Rabaneck L: Extra-hepatic manifestations of hepatitis C among United States male veterans. *Hepatology* 2002;36:1439–1445.
- 37 Perico N, Cattaneo D, Bibkov B, Remuzzi G: Hepatitis C infection and chronic renal diseases. *Clin J Am Soc Nephrol* 2009;4:207–220.
- 38 Sneller M, Hu Z, Langford C: A randomized controlled trial of rituximab following failure of antiviral therapy for hepatitis C virus-associated cryoglobulinemic vasculitis. *Arthritis Rheum* 2012;64:835–842.
- 39 Basse G, Ribes D, Kamar N, Mehrenberger M, Sallusto F, Esposito L, Guitard J, Lavaysiere L, Oksman F, Durand D, Rostaing L: Rituximab therapy for mixed cryoglobulinemia in seven renal transplant patients. *Transplant Proc* 2006;38:2308–2310.
- 40 Fabrizi F, Martin P, Elli A, Montagnino G, Banfi G, Passerini P, Campise R, Tarantino A, Ponticelli C: Hepatitis C virus infection and rituximab therapy after renal transplantation. *Int J Artif Organs* 2007;30:445–449.
- 41 McHutchison JG, Everson GT, Gordon SC, Jacobson I, Sulkowski M, Kauffman R, McNair L, Alam J, Muir A, PROVE1 Study Team: Telaprevir with peginterferon and ribavirin for chronic HCV genotype 1 infection. *N Engl J Med* 2009;360:1827–1838.
- 42 Hezode C, Forestier N, Dusheiko G, Ferenci P, Pol S, Goeser T, Browicki J, Bourliere M, Gharakhanian S, Bengtsson L, McNair L, George S, Kieffer T, Kwong A, Kauffman R, Alam J, Pawlotsky J, Zeuzem S, PROVE2 Study Team: Telaprevir and peginterferon with or without ribavirin for chronic HCV infection. *N Engl J Med* 2009;360:1839–1850.
- 43 Ghany G, Nelson D, Strader D, Thomas D, Seeff L: An update on treatment of genotype 1 chronic hepatitis C virus infection: 2011 practice guidelines by the American Association for the Study of Liver Diseases. *Hepatology* 2011;54:1433–1434.
- 44 Saadoun D, Rosenzweig M, Joly F, Six A, Carrat F, Thibault V, Sene D, Cacoub P, Klatzmann D: Regulatory T-cell responses to low-dose interleukin-2 in HCV-induced vasculitis. *N Engl J Med* 2011;365:2067–2077.